



PATIENT

Ella Ramsey

SPECIES

Canine

BREED

Pitbull Mix

SEX

Female Spayed

AGE

9.6.11

WEIGHT

56.7lbs

INTERPRETED BY

Maggie Machen Lamy,
DVM, DACVIM
(Cardiology)

HOSPITAL NAME

Animal Emergency
Hospital

REFERRING VET

Dr. Martinoli

INVOICE

25350

DATE

7.15.22

PRESENTING CLINICAL SIGNS

History: Had mast cell tumor removed -- left ear pinna -- good margins, a couple years ago. Last year was diagnosed with chemodectoma (heart-based mass) and has received radiation for it; has shrank about 50%. About a month ago she had diarrhea; went to ER at home (owner from Michigan; is in town here visiting family); Ella also had UTI at the time so was treated with Augmentin and Meloxicam; also got Fortiflora. She recovered fairly quickly but recently got diarrhea again and today has been vomiting frequently. Diarrhea has gotten bloody.

-Current medications: Provable, Gabapentin, Métronidazole, Cerenia.

-Sedation used: Not required to complete full diagnostic ultrasound.

-Pertinent previous ultrasound results: No previous.

-STAT: Not requested

-Imaging performed by: Andi Parkinson, BS, RDMS.

ECHOCARDIOGRAM FINDINGS

2D, m-mode, color flow and doppler imaging is available. Diffuse thickening of mitral valve leaflets with minimal prolapse into the left atrial lumen. Moderate mitral regurgitation moderate left atrial dilation. Normal MR velocity. Borderline LV diameter with mild myocardial dysfunction. The tricuspid valve appears mildly thickened with mild tricuspid regurgitation. Velocity consistent with early pulmonary hypertension. No significant right heart enlargement. The pulmonic and aortic valves are normal in morphology and mobility. Normal pulmonic and aortic outflow velocities with laminar flow. No obvious aortic or pulmonic insufficiency. No pericardial or pleural effusion noted. A large mass is visualized adjacent to the heart base; 7.0cm x 8.6cm in best-viewed cross section.

CARDIAC CHART

CANINE CARDIAC PARAMETERS	MR VMAX (m/s)	TR VMAX (m/s)	LA/AO (Boon method)	LA/AO (Heart Base; Swe)	FS (%)	EF (%)	EPSS (cm)
NORMAL PARAMETER	4.5-5.5	<2.7	1.3	<1.6	28-40	40-100	<0.6
PATIENT	5.1	3.14	NM	1.7	26	50	NM
CANINE CARDIAC PARAMETERS	HR (BPM)	AV VMAX (m/s)	PV MAX (m/s)	BODY WEIGHT (kg)	LA 2D short axis Base view (cm)	LVIDd Avg; 2D and m-mode short axis (cm)	LVIDs Avg; 2D and m-mode short axis (cm)
NORMAL PARAMETER	50-100	0.7-1.7	0.7-1.6	BELOW	BELOW	BELOW	BELOW
PATIENT	120	1.2	0.59	25.7	3.8	4.6	3.4
*Normal chamber parameters expressed as a mean value (SD)				3	1.27 (5.3)	2.46 (2.46)	1.36 (5.5)
BODY WEIGHT DEPENDENT PARAMETERS							
<i>*Note: All measurements based upon multi-modal images and methods. An average value is reported.</i>							
Adapted from June Boon, Veterinary Echocardiography, 1998 Rishniw M and Hollis NE, J Vet Intern Med 2000; 14:429-435 Hansson et al, Vet Rad and Ultrasound 2002 Bonagura et al. Echocardiography: principles of interpretation, Vet Clin North Am 15:1177, 1995				5	1.40 (4.5)	2.74 (5.2)	1.60 (4.7)
				10	1.50 (3.8)	3.27 (3.5)	2.06 (3.1)
				15	1.83 (2.0)	3.71 (2.4)	2.43 (2.1)
				20	2.02 (1.9)	4.14 (2.2)	2.80 (2.0)
				25	2.18 (2.4)	4.48 (2.9)	3.10 (2.5)
				30	2.33 (3.3)	4.83 (3.9)	3.39 (3.4)
				35	2.48 (4.3)	5.17 (5.0)	3.69 (4.5)
				40	2.62 (5.2)	5.48 (6.1)	3.96 (5.4)
50	2.88 (7.1)	6.07 (8.3)	4.46 (7.4)				

INTERPRETATION OF THE FINDINGS & FURTHER RECOMMENDATIONS

Chronic degenerative valve disease causing moderate mitral and mild tricuspid regurgitation is identified. Moderate left atrial enlargement indicates the current risk for complication is low however risk for progression is high. Additionally, mild LV dysfunction is noted, which should be monitored going forward. Mild pulmonary hypertension is present, which is likely secondary to the large heart based tumor. No additional issues are identified.

The previously documented chemodectoma is readily apparent on this exam. Without specific measurements and images for comparison, it is difficult to say if this has progressed or is stable comparatively. Regardless, there is no obvious chamber compression or development of effusions at this time. Given that the patient has developed GI upset, consider systemic screening through AUS, full lab work, etc. Additionally, a thoracic CT can be considered for definitively mass measurements and help dictate long-term picture. Regardless, what is seen here specifically does not necessarily impact GI signs. It is certainly possible that a metastatic lesion has developed however, which may be related. Follow up is advised.

Given the totality of findings, I do recommend Pimobendan in this case as below. **This is for long-term benefit and should not be instituted until vomiting and diarrhea has resolved.** Omega fatty acid supplementation and mild salt restriction may be of some long-term benefit. Monitor for development of a cough, labored breathing, exercise intolerance or collapse episodes. Patient will always be at risk for development of congestive signs (ascites most common), collapse episodes, development of arrhythmias and/or sudden death going forward.

The prognosis with cardiac chemodectomas is fair. The limiting factor is often hemorrhage into the pericardium, impingement of cardiac blood flow secondary to tumor growth, or metastasis to the thorax or abdomen.

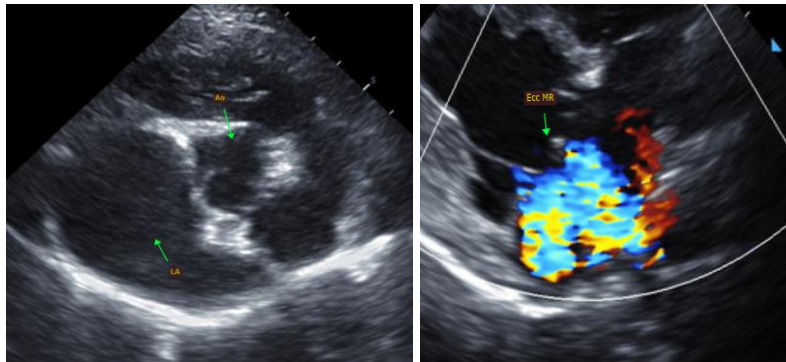
Once on the medication for 3-5 days, anesthetic risk is considered moderately elevated. Cardiac protective drug choices (opioid/benzodiazepine premedication, Propofol or alfaxalone induction, iso or sevo gas) are recommended. Monitor for arrhythmias, hypotension, and hypoxia both intra and post-operatively and intervene as necessary. Judicious IV fluid rates are recommended to avoid fluid overload. Avoid heart rate stimulating drugs such as atropine unless clinically indicated.

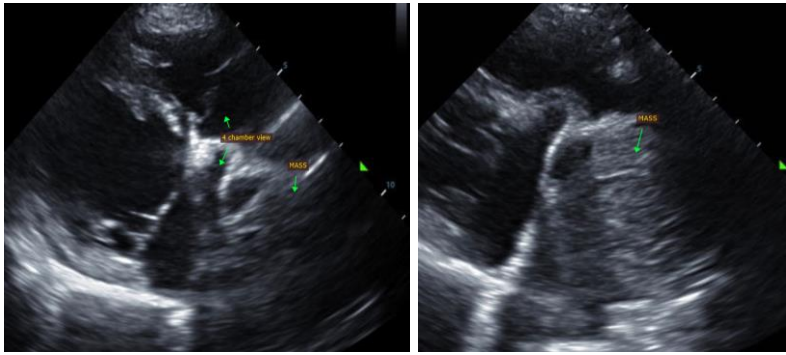
PLAN

Institute Pimobendan 0.3mg/kg PO q12h. Consider full systemic evaluation as discussed. Consider advanced imaging as discussed.

If patient improves and does well, recommend recheck echocardiogram in 6 months.

IMAGES





The information and recommendations provided are based on the images presented by the referring veterinarian. No evaluation can be communicated regarding pathology that was not visible in the image/video clips provided.

Thank you for this referral. This report was generated using transcription software, and minor dictation errors may be present. If the clinical or image interpretation does not parallel your findings or if I can be of any further assistance, please contact me.

Maggie Machen Lamy, DVM
Diplomate of the American College of Veterinary Internal Medicine (Cardiology)
info@sonopath.com